

The cerebellar cognitive affective syndrome

Jeremy D. Schmahmann and Janet C. Sherman

Department of Neurology, Massachusetts General Hospital and Harvard Medical School, Boston, USA

Correspondence to: Jeremy D. Schmahmann, MD, Department of Neurology, Massachusetts General Hospital, VBK 915, Fruit Street, Boston, MA 02114, USA

Summary

Anatomical, physiological and functional neuroimaging studies suggest that the cerebellum participates in the organization of higher order function, but there are very few descriptions of clinically relevant cases that address this possibility. We performed neurological examinations, bedside mental state tests, neuropsychological studies and anatomical neuroimaging on 20 patients with diseases confined to the cerebellum, and evaluated the nature and severity of the changes in neurological and mental function. Behavioural changes were clinically prominent in patients with lesions involving the posterior lobe of the cerebellum and the vermis, and in some cases they were the most noticeable aspects of the presentation. These changes were characterized by: impairment of executive functions such as planning, set-

shifting, verbal fluency, abstract reasoning and working memory; difficulties with spatial cognition including visual-spatial organization and memory; personality change with blunting of affect or disinhibited and inappropriate behaviour; and language deficits including agrammatism and dysprosodia. Lesions of the anterior lobe of the cerebellum produced only minor changes in executive and visual-spatial functions. We have called this newly defined clinical entity the 'cerebellar cognitive affective syndrome'. The constellation of deficits is suggestive of disruption of the cerebellar modulation of neural circuits that link prefrontal, posterior parietal, superior temporal and limbic cortices with the cerebellum.

Keywords: cerebellum; cognition; intellect; affect; behaviour

Abbreviations: AICA = anterior inferior cerebellar artery; PICA = posterior inferior cerebellar artery; SCA = superior cerebellar artery; SPECT = single photon emission tomography

Introduction

It is well established in clinical neurology and neuroscience that the cerebellum is essential for the co-ordination of movement (Flourens, 1824; Luciani, 1891; Holmes). Less attention has been directed to the observation that behavioural anomalies occur in association with cerebellar disorders (Combettes, 1831; Andral, 1848; Knoepfel and Macken, 1947; see also Dow and Moruzzi, 1958; Watson, 1978; Heath *et al.*, 1979; Schmahmann 1991, 1997a). The early reports were generally anecdotal and not pathologically verified, and the possibility of a cerebellar contribution to non-motor function was largely dismissed.

Recently, evidence has been presented that patients with cerebellar degeneration or stroke do indeed have cognitive dysfunction related to the cerebellar disorder itself. Kish *et al.* (1988) and Bracke-Tolkmitt *et al.* (1989) described difficulties with concept formation, learning of paired-associates, and generalized intellectual slowing in patients with olivopontocerebellar atrophy. Patients with cerebellar cortical atrophy were found to have impaired executive

function demonstrated by increased planning times when performing the Tower of Hanoi Test (Grafman *et al.*, 1992), and by poor performance on tests of fluency and the initiation/perseveration subtest of the Mattis Dementia Rating Scale (Appollonio *et al.*, 1993). Visual spatial deficits were described following excision of left cerebellar hemisphere tumours (Wallesch and Horn, 1990), in the setting of chronic phenytoin intoxication (Botez *et al.*, 1985), and after left superior cerebellar artery territory infarction (Botez-Marquard *et al.*, 1994). Linguistic processing was impaired in patients with right cerebellar infarction as evidenced by agrammatism in one case (Silveri *et al.*, 1994) and impaired error detection and practice-related learning of a verb-for-noun generation task in another (Fiez *et al.*, 1992). More severe language impairments have been noticed in children with cerebellar lesions. Mutism and subsequent dysarthria are now recognized following excision of cerebellar tumours (Kingma *et al.*, 1994; van Dongen *et al.*, 1994; Pollack *et al.*, 1995), accompanied in many instances by regressive personality

changes, emotional lability and poor initiation of voluntary movement (Pollack *et al.*, 1995). Levisohn *et al.* (1997) also reported problems with expressive language and visual spatial functions in children who have undergone excision of cerebellar tumours. Furthermore, they noted dramatic mood swings and uncharacteristic giddiness in eight of 14 patients with damage to the vermis, whereas these personality changes were not present when the vermis was unaffected. Patients with early infantile autism have been shown to have abnormalities in the cerebellum on both morphometric and neuroimaging studies (Bauman and Kemper, 1985; Courchesne *et al.*, 1988). These and other initial clinical observations have been bolstered by functional neuroimaging experiments showing cerebellar activation by non-motor tasks (Petersen *et al.*, 1989; Allen *et al.*, 1997; Fiez and Raichle, 1997; Parsons and Fox, 1997) and by anatomical findings, physiological and behavioural studies, and theoretical notions (see Schmahmann 1996, 1997b) that suggest a role for the cerebellum in cognitive processing and emotion.

A persistent concern shared by investigators and clinicians is that there are very few descriptions of clinically relevant cases that address the possibility of a cerebellar contribution to non-motor behaviours. The detection of deficits by subtle neuropsychological tests alone would appear to be insufficient grounds to warrant a revision of the understanding of the role of the cerebellum. We have therefore performed neurological examinations, bedside mental state tests, and neuropsychological evaluations on patients with diseases confined to the cerebellum, in order to determine whether there is a predictable pattern of clinically relevant cognitive and behavioural changes in these patients. Our results indicate that there is a pattern of behavioural abnormalities, termed the 'cerebellar cognitive affective syndrome', that includes impairments of executive function (planning, set-shifting, abstract reasoning, verbal fluency, working memory), often with perseveration, distractibility or inattention; visual-spatial disorganization and impaired visual-spatial memory; personality change with blunting of affect or disinhibited and inappropriate behaviour; and difficulties with language production including dysprosodia, agrammatism and mild anomia. The net effect of these disturbances in cognitive abilities appears to be a general lowering of intellectual function. These findings were more pronounced in patients with bilateral and acute disease. Posterior lobe lesions were particularly important in the generation of the syndrome, and the vermis was consistently involved in patients with pronounced affective presentations. This report presents the findings in these patients, including selected detailed case histories.

Methods

Subject selection and study design

Patients with cerebellar pathology were referred to the Department of Neurology at the Massachusetts General

Hospital over a 7-year period (July 1989 to August 1996). Patients were not selected specifically for the presence of cognitive disturbance in the setting of cerebellar disease. Patients were excluded from detailed study for the following reasons: age >75 years; non-cerebellar white matter hyperintensities on MRI; other areas of lesions such as infarction or haemorrhage involving the cerebral hemispheres; major neurological diseases (e.g. Alzheimer's disease, Parkinson's disease or epilepsy); pre-existent psychiatric diagnoses; history of drug or alcohol abuse, head trauma or central nervous system infection; medical conditions such as hepatic, renal and pulmonary disease, systemic infection or metabolic encephalopathy; current use of psychoactive or sedating medications; abnormal elementary neurological examination (other than cerebellar dysfunction) including extensor plantar responses, extrapyramidal findings and peripheral polyneuropathy.

Each patient received a comprehensive medical evaluation, neurological examination and bedside mental state testing, as well as MRI and EEG. Patients were evaluated neurologically between 1 week and 6 years from the onset of the illness. Some patients were seen in follow-up 1 month to 5 years after the first evaluation so that the progression of the neurological and mental state findings, as well as the neuropsychological features, could be documented. All patients were referred for neuropsychological study, but some were discharged from hospital prior to testing and were lost to follow-up. The specific tests and procedures that were administered are described below.

Bedside mental state evaluation

The mental state examination was conducted according to established clinical methods (Weintraub and Mesulam, 1985; Hodges, 1994). The degree of impairment was graded on a three-point scale, from mild (+) to severe (+++). For purposes of graphic comparison of the data, a severity score of functional impairment was generated. The severity score represents the sum of the plus signs in each major category of deficit, expressed as a ratio of the total number of tests within each category that was actually administered to patients multiplied by three (the maximum possible abnormal score for each test). This method permitted a semi-quantitative comparison of the deficits across functional categories and between patients.

Clinical investigations

T₁- and T₂-weighted MRI or CT were performed according to standard protocols. The localization of the lesion and the vascular territory of those cases with infarction was based on the work of Amarenco (1991). Electroencephalographic studies were performed on an 18-channel Grass monitor. In two cases single photon emission tomography (SPECT) was performed using [^{99m}Tc]HMPAO, and a PET scan was

performed in one patient using 9.8 mBq of [¹⁸F]-fluorodeoxyglucose, in order to assess cerebral perfusion.

Neuropsychological studies

Patients received neuropsychological testing either by one of us (J.C.S.) or by another psychologist during their in-patient stay, or as out-patients in the Massachusetts General Hospital Neuropsychology Laboratory. Not all tests were administered to all patients, as patients were studied prospectively in the clinical setting, and in some cases motor problems precluded tests dependent upon voluntary movement. Most patients were administered the Wechsler Adult Intelligence Scale—Revised (WAIS-R; Wechsler, 1981), Wechsler Memory Scale—Revised (WMS-R; Wechsler, 1987), Rey/Taylor Complex Figure Test (copy and memory formats; Rey, 1941; Kolb and Wishaw, 1985), Controlled Oral Word Association Test (F-A-S; Yeudell *et al.*, 1986; Spreen and Strauss, 1991), Animal-Naming Test (Spreen and Strauss, 1991), Stroop Color and Word Test (Golden, 1978), Trail Making Test (Army Individual Test Battery, 1944; Alekoumbides *et al.*, 1987), Wisconsin Card Sorting Test (Heaton *et al.*, 1993), Porteus Maze Test (Porteus, 1965), Hooper Visual Organization Test (Hooper, 1983), Boston Naming Test (Kaplan *et al.*, 1983) and Peabody Picture Vocabulary Test—Revised (Dunn and Dunn, 1981). Other tests administered included the Wechsler Intelligence Scale for Children—III (WISC—III; Wechsler, 1991), California Verbal Learning Test (CVLT; Delis *et al.*, 1987), Written Fluency Test (H-words, Reitan, 1979), Raven's Standard Progressive Matrices (Raven *et al.*, 1976), Benton Judgment of Line Orientation Test (Benton *et al.*, 1983), Benton Face Recognition Test (Benton *et al.*, 1983), Tower of Hanoi Test (Shallice, 1982; Shallice and Burgess, 1991) and the Wide Range Achievement Test—3 (Wilkinson, 1993).

All of the tests administered are standardized measures with published normative data (as referenced above). The performance of the patients on each of these measures was compared with the normative data provided for each test. In order to obtain a standardized score, raw scores were compared with the mean score for individuals of the same age, and when provided by the test, the same gender and level of education. All test scores are based on a mean and standard deviation, but are expressed differently for different tests with some, for example, providing Standard Scores [as for IQ scores where the mean = 100 and standard deviation (SD) = 15], some providing *t*-scores (mean = 50 and SD = 10), some percentile scores, and some providing a mean and standard deviation for age-matched samples with which a patient's raw score is compared. Given the need to compare the performance of the patients on tests of different functional domains, all scores were converted to *Z*-scores. The *Z*-score provides a standard from which all other scores can be derived, and it reflects the amount that a score deviates from the mean of that population. *Z*-scores are obtained by the formula [(subject) – (population mean)/(SD for the

population)]. Scores are therefore stated in standard deviation units, and reflect their distance from the mean.

Results

Patients' characteristics

A total of 20 patients were studied. There were 12 men and eight women. The age range of the study group was 23–74 years (mean age 48.2 years), excluding one 12-year-old boy. The mean level of education was 13.9 years. Thirteen patients suffered stroke, three had postinfectious cerebellitis, three had cerebellar cortical atrophy, and one had a midline cerebellar tumour resected. The EEGs in all patients were normal, showing no evidence of diffuse or focal slowing, and no epileptiform activity was detected. The locations of the focal lesions are described in Table 1 and are further detailed in the case reports. No record was kept over the 7-year period of the number of patients who did not meet the inclusion criteria, but the most common reason preventing inclusion into the study was that MRI demonstrated involvement of brain regions other than the cerebellum, either at the time of the new event or at some point in the past.

Summary of results

Elementary neurological examination

The patients with pancerebellar involvement (Cases 15–20) demonstrated incoordination of arms and legs; unstable (ataxic) gait; dysarthria; and eye movement abnormalities including nystagmus, saccadic breakdown of pursuit, hypometric and hypermetric saccades, periodic alternating nystagmus and square wave jerks at rest, and failure to suppress the vestibulo-ocular reflex. Patients 2 and 3 with bilateral cerebellar infarction were motorically quite compromised by inco-ordination, but improved over the ensuing months. They could ambulate independently, but experienced ongoing cerebellar motor abnormalities in addition to a persistent personality change. The motor disturbances in patients with unilateral infarction in the posterior inferior cerebellar artery (PICA), anterior inferior cerebellar artery (AICA) or superior cerebellar artery (SCA) territories were mild, involved the limbs more than the trunk, and resolved after a few weeks. The patient with cerebellar vermis excision for tumour (ganglioglioma) had a minimally abnormal elementary neurological examination at the time of the behavioural change. Strong bilateral palmar grasp reflexes were observed in some patients with pancerebellar or bilateral disease of recent onset. Three patients underwent posterior fossa decompression within hours of acute infarction (Cases 4, 9 and 10) because of threatened hydrocephalus (drowsiness, cerebellar mass effect on the fourth ventricle). Neuroimaging performed the day after surgery in these patients showed no evidence of hydrocephalus, and all patients were alert and cooperative during the bedside neurological testing.

Table 1 Patient characteristics

Patient	Age (years)	Education (years)	Diagnosis	Interval: onset-examination
1	23	16	Midline/paravermis resection	1 week
2	44	12	Bilateral PICA stroke	1 month
3	57	20	Bilateral PICA stroke	2 weeks
4	32	16	Right PICA stroke	2 weeks
5	62	18	Right PICA stroke	2 weeks
6	74	12	Right PICA stroke	2 weeks
7	56	12	Right PICA (medial) stroke	1 month
8	58	18	Right PICA (branch) stroke	2 years
9	67	12	Left PICA stroke	1 week
10	66	9	Left PICA stroke	2 weeks
11	58	12	Left PICA stroke	2 weeks
12	50	16	Right AICA stroke	1 week
13	58	12	Left SCA stroke	2 weeks
14	36	12	Right SCA stroke	1 week
15	22	16	Postinfectious cerebellitis	1 month
16	12	Grade 6	Postinfectious cerebellitis	1 month
17	42	12	Postinfectious cerebellitis	3 months
18	24	12	Cerebellar cortical atrophy	6 years
19	31	16	Cerebellar cortical atrophy	4 years
20	56	12	Cerebellar cortical atrophy	5 years

AICA = anterior inferior cerebellar artery; PICA = posterior inferior cerebellar artery; SCA = superior cerebellar artery.

Bedside mental state testing

All patients were awake, cooperative and able to give an account of their history, although the level of attention was variable. No patient demonstrated a standard clinical aphasic syndrome, hemispatial neglect, or agnosia. In contrast, the behaviour of these patients was abnormal in varying degrees of severity, with features that differed according to lesion site and acuity of onset. The performance of each patient on these tests is listed in Table 2. The results from all the patients, grouped according to functional category, are presented in Fig. 1.

Those with bihemispheric infarction (Cases 2 and 3), pancerebellar disease (Cases 15–20), and large unilateral PICA lesions (Cases 4, 5, 6, 9 and 10) were affected in a manner that was clinically obvious. The two patients with small right PICA infarcts (Cases 7 and 8), and the two with small right AICA or SCA territory infarcts (Cases 12 and 14) were only mildly affected. Eighteen of the 20 patients demonstrated problems with executive functions. Working memory was poor in 11 (of 16 tested), motor or ideational set shifting in 16 (of 19), and perseveration of actions or drawings was noted in 16 (of 20). Verbal fluency was impaired with specific testing in 18 patients, and in some this was clinically evident as telegraphic speech. In two, speech output was so limited as to resemble mutism. Decreased verbal fluency was unrelated to dysarthria. Some patients with minimal dysarthria in the setting of acute lesions performed more poorly on fluency tests than others with severe dysarthria and disease of greater duration.

Visuospatial disintegration, most marked in attempts to draw or copy a diagram, was found in 19 patients, regardless

of lesion acuity or severity of the dysmetria. The sequential approach to the drawing of the diagrams, and the conceptualization of the figures was disorganized. Four patients demonstrated simultanagnosia.

Naming was impaired in 13 patients, generally being spared in those with smaller lesions. Six patients had agrammatic speech, most notably those with bilateral acute disease. Elements of abnormal syntactic structure were noted in others, but less prominently. Prosody was abnormal in eight patients, with tone of voice characterized by a high pitched, whining, childish and hypophonic quality.

Mental arithmetic was deficient in 14 patients. Verbal learning and recall were mildly abnormal in 11, and visual learning and recall were impaired in four (of 13 patients tested). Ideational apraxia was evident in two individuals.

A prominent feature of the bedside mental state examination in 15 patients was the presence of difficulty in modulation of behaviour and personality style. The notable exceptions were those patients whose strokes were either very limited in size, or confined to the anterior lobe. Flattening of affect or disinhibition were manifested as overfamiliarity, flamboyant and impulsive actions, and humorous but inappropriate and flippant comments. Behaviour was regressive and childlike, particularly following large or bilateral PICA territory infarcts, and in the patient with surgical excision of the vermis and paravermian structures. Obsessive compulsive traits were occasionally observed.

Autonomic changes were the central feature in one patient, whose stroke in a medial branch of the right PICA involved the fastigial nucleus and paravermian cortex region. This manifested as spells of hiccuping and coughing which precipitated bradycardia and syncope.

Table 2 Findings of mental state examinations of Cases 1–20

	Mid-line			Bilateral PICA			R-PICA			L-PICA			R-AICA			L-SCA			R-SCA			Cerebellitis				Cerebellar cortical atrophy				
	1	2	3	4	5	6	7	8	9	10	11	12	13	13	13	13	13	13	13	13	13	13	15	16	17	18	19	20		
Arousal/alertness	0	++	0	0	0	+	0	0	0	+	0	0	0	0	0	0	0	0	0	0	0	0	0	0	0	0	0	0	+	
Attention: observation	-	0	0	-	0	0	0	-	0	-	-	0	0	0	0	0	0	0	0	0	0	0	0	0	0	0	0	0	+	
Attention: letter A	0	0	+	0	0	-	0	0	-	++	-	0	0	0	0	0	0	0	0	0	0	0	0	0	0	0	0	0	+	
Concentration (forward digit span)																														
Executive																														
Working memory (reverse digit span)	++	+++	+	-	+	+	0	0	-	+++	-	0	0	0	0	0	0	0	0	0	0	0	0	0	0	0	0	0	+	
Set shifting: motor (fist-palm-side)	++	+++	++	++	+	+	0	0	+	+	++	+	+	+	+	+	+	+	+	+	+	+	+	+	+	+	+	+	+	
Set shifting: ideational (alternating lists)	-	-	-	-	-	-	-	-	-	-	-	-	-	-	-	-	-	-	-	-	-	-	-	-	-	-	-	-	-	
Perseveration: Luria diagram	++	++	-	+	++	++	0	0	+	++	+	0	0	0	0	0	0	0	0	0	0	0	0	0	0	0	0	0	0	
Perseveration: other (verbal/written)	++	+++	++	+	+	+	0	0	0	++	0	0	0	0	0	0	0	0	0	0	0	0	0	0	0	0	0	0	0	
Go-no-go/delayed alternation	-	-	+	++	-	-	-	-	-	-	-	-	-	-	-	-	-	-	-	-	-	-	-	-	-	-	-	-	-	
Verbal fluency (semantic)	+++	+++	+	+	+++	+++	0	0	++	++	++	+	+	+	+	+	+	+	+	+	+	+	+	+	+	+	+	+	+	
Reasoning and abstraction																														
Similarities/proverb interpretation	++	++	+	++	++	++	0	0	++	+	+	0	0	0	0	0	0	0	0	0	0	0	0	0	0	0	0	0	0	+
Visuospatial																														
Draw/copy	++	++	++	++	+	+++	++	+	0	+	+	+	+	+	+	+	+	+	+	+	+	+	+	+	+	+	+	+	+	+
Simultagnosia	++	+	0	0	0	+	0	0	0	0	0	0	0	0	0	0	0	0	0	0	0	0	0	0	0	0	0	0	0	0
Language																														
Naming	+	+	+	++	++	+	0	+	++	+	0	0	0	0	0	0	0	0	0	0	0	0	0	0	0	0	0	0	0	0
Agrammatism/stuttering	+	++	+	+	0	+	0	0	0	0	0	+	0	0	0	0	0	0	0	0	0	0	0	0	0	0	0	0	0	0
Dysprosody	+++	++	++	++	0	0	0	0	0	0	0	0	0	0	0	0	0	0	0	0	0	0	0	0	0	0	0	0	0	0
Memory																														
Verbal learning and recall	0	+++	0	+	+	+	0	+	++	+	0	0	0	0	0	0	0	0	0	0	0	0	0	0	0	0	0	0	0	+
Visual learning and recall	0	-	0	-	0	+	-	0	-	0	-	0	0	0	0	0	0	0	0	0	0	0	0	0	0	0	0	0	0	+
Specific																														
Calculation	+++	++	0	++	++	+	0	+	+	+++	0	0	0	0	0	0	0	0	0	0	0	0	0	0	0	0	0	0	0	+
Affect/limbic	+	+	++	++	+	++	0	0	0	++	0	0	0	0	0	0	0	0	0	0	0	0	0	0	0	0	0	0	0	0
Flattened affect	+++	+++	+++	++	+	++	0	+	++	0	0	0	0	0	0	0	0	0	0	0	0	0	0	0	0	0	0	0	0	0
Disinhibited	+++	+++	+++	++	+	++	0	+	++	0	0	0	0	0	0	0	0	0	0	0	0	0	0	0	0	0	0	0	0	0

AICA = anterior inferior cerebellar artery; PICA = posterior inferior cerebellar artery; SCA = superior cerebellar artery. 0 = normal; + = mildly abnormal; ++ = moderately abnormal; +++ = severely abnormal; - = not tested. The infarct in Case 7 involved the medial right PICA territory including fastigial nucleus, and in Case 8 it involved a small right hemispheric PICA branch. (Remote memory was mildly abnormal in Cases 6, 13, 19 and 20; mild limb apraxia was observed in Cases 2 and 6; bradycardia with heart rate into the 20s and syncope was documented in Case 7. These findings are not included in the table.)

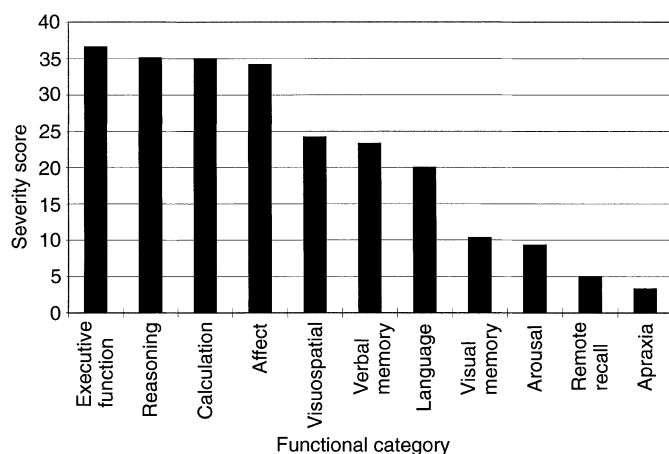


Fig. 1 Bar graph depicting the deficits found on bedside mental state testing in this series of patients with cerebellar lesions. The severity score indicates the relative degree of impairment within each major functional category. This score is the sum of the plus signs in each major category of deficit in Table 2, expressed as a ratio of the total number of tests within each category actually administered to patients, multiplied by three (the maximum possible abnormal score for each test).

Neuropsychological testing

The neuropsychological studies confirmed a number of the clinical findings, further extended our understanding of the cognitive abnormalities encountered, and provided objective evidence of a decline in the level of intellectual functioning in many of the patients tested. Table 3 summarizes the results. Figure 2 shows the distribution of Z-scores for the patients (grouped according to disease type) on the different neuropsychological tests. These findings were in agreement with the observations from the bedside mental state tests with respect to the nature of the deficits detected.

The distribution of patients' scores differed significantly from the normal distribution, with the most marked deviation from normal evident in the categories of executive and visual spatial function. Attention and orientation, and language functions more closely approximated a normal distribution of scores. In addition, performance on the Porteus Mazes Task (a test of visual spatial planning) was very poor, with all subjects scoring at or below a test age of 12 years. (These results were not included in the analysis because test scores are reported only in the form of test age.) Our results also showed that patients with bilateral lesions and posterior lobe lesions were most impaired, and those with small lesions, or in whom disease was confined to the anterior lobe of the cerebellum, were least affected.

Time course

Four patients with acute cerebellar injury underwent a repeat neuropsychological evaluation at a later point in their course (1–9 months after onset). This sample size does not allow for a statistical comparison, but a comparison of mean test performance in the first and second visits indicates that the

impairments documented on initial presentation generally improved over time (Fig. 3). Mean test scores at the second evaluation more consistently fell within normal limits, although most notably, executive function remained 1 SD below the mean on repeat testing.

One patient with cerebellar cortical atrophy (Patient 18) was tested three times over a period of 3 years. In contrast to the patients with acute cerebellar lesions, performance on neuropsychological tests generally worsened over time. Declining function was particularly evident in the areas of visual spatial abilities, concept formation and verbal memory.

Patient reports

In order to convey a finer sense of the clinical presentation and behavioural abnormalities in these patients, selected case histories are presented in more detail.

Midline cerebellar tumour excision

Case 1. The original case in this series (discussed briefly in Schmahmann, 1991) was a 22-year-old right-handed female college student. A midline cerebellar tumour (ganglioglioma) was diagnosed after a head CT scan was performed following a slip on ice. The tumour was resected uneventfully. Neurological consultation was requested for a persistent and odd behavioural syndrome in the postoperative period. Immediately postoperatively she was responsive but somnolent, and she followed commands but was soft spoken. Nurses noted a flat affect, and family noted a personality change. She was behaving inappropriately, whining, undressing in the corridors, and talking with her mouth full of food. This did not improve over a period of 9 days. On examination she demonstrated saccadic pursuit, minimal horizontal gaze-evoked nystagmus, and failure of suppression of the vestibular ocular reflex. Rapid alternating movements of the left hand were minimally impaired. She could stand with her feet together and arms outstretched, although gait was slow with small steps, and tandem gait was slightly unsteady. There were no palmar grasps. MRI showed no abnormalities outside the cerebellum (Fig. 4). SPECT showed the postoperative defect in the cerebellum, with hypoperfusion in most of the left temporal lobe and particularly the rostral two thirds, the left prefrontal region and bilaterally in the parietal lobes. Increased perfusion in the left thalamus was also appreciated.

The patient's speech was quick, unintelligible, and she was speaking 'baby-talk' in a high pitched voice. She talked with her head down, covered her face with the bed sheets, and assumed the foetal position. She was curled up in bed, repeatedly pulling the covers over her head, and she needed to be coaxed to cooperate with the examination. She was alert, fully oriented to her history, the events of the day, and the names of her physicians. She repeated seven numbers forwards, but only three in reverse sequence. She was unable to subtract serial threes, and would lose track of the task.

Table 3 Neuropsychological results grouped according to major functional category

Test	Abbreviation	Z-score		P-value	n
		Mean	SD		
Intellectual functioning					
WAIS—R Full-scale IQ	FSIQ	-1.0	0.123	0.0002***	13
WAIS—R Verbal IQ	VIQ	-0.93	0.145	<0.0001***	15
WAIS—R Performance IQ	PIQ	-1.3	0.127	0.0006***	13
Executive functioning					
Word Association	FAS	-2.7	1.8	<0.0001***	16
Animal Naming		-1.5	0.77	0.0002***	10
Trails A		-1.2	1.3	0.0067**	12
Trails B		-0.89	0.76	0.0030**	11
Wisconsin Card Sorting Test	WCST	-0.83	1.7	0.2205	8
Reasoning and abstraction					
Similarities	WAIS—R Sims	-0.42	0.99	0.1141	16
Comprehension	Compr.	-0.79	0.67	0.0120*	8
Picture Completion		-0.77	0.98	0.0150*	13
Arithmetic	Arith.	-0.86	1.1	0.0112*	13
Picture Arrangement		-1.4	0.74	<0.0001***	14
Visuospatial/visual construction					
Rey Complex Figure: Copy		-5.9	3.2	0.0002***	13
WAIS—R Block Design		-1.2	0.90	0.0006***	12
WAIS—R Object Assembly		-0.81	0.84	0.0431*	7
Hooper Visual Orientation	HVOT	-0.42	0.89	0.3038	6
Language					
Boston Naming Test BNT		-1.4	1.4	0.0047**	13
Peabody Picture Vocab. PPVT-R		-0.40	1.4	0.6097	4
WAIS—R Vocabulary	Vocab.	-0.13	1.3	0.7448	10
WAIS—R Information	Info.	-0.51	0.93	0.0501	15
Attention and orientation					
Digit Span—forward		-0.51	1.3	0.1501	15
Digit Span—backward		-0.61	1.2	0.0644	15
Tapping Span—forward		-0.78	1.0	0.0844	7
Tapping Span—backward		-0.85	0.84	0.0571	7
Digit Symbol		-1.3	0.67	0.0004***	9
Stroop		0.07	0.95	0.8769	4
Memory WMS-R					
Logical Memory I	LM I	-0.40	1.1	0.1756	14
Logical Memory II	LM II	-0.42	0.89	0.1046	14
Visual Reproduction I	VR I	-1.1	1.1	0.0038**	12
Visual Reproduction II	VR II	-1.4	0.84	0.0001***	12
Rey Complex Figure: Memory		-1.7	0.76	0.0012**	7

n = number of patients who received each test. ***P < 0.001; **P < 0.01; *P < 0.05.

She made multiple errors also with subtracting serial sevens. She persisted with this difficulty when the numbers were written down for her. She learned and recalled four words at 5 min, and she recalled the nature and hiding places of four objects hidden around the room after 5 min. She made errors naming common items, but repetition and comprehension were intact. She perseverated on motor and verbal responses, in writing and line bisection, and when copying the Luria diagram. She had difficulty switching set with the fist-palm-side test. Her illustrations were rudimentary and quite abnormal. Word list generation was poor, naming only seven animals in 1 min. Abstraction as tested by similarities was simple, and she often missed the point. (Similarity between a dog and a cat: 'a dog is brown'.) Interpretation of proverbs was concrete and essentially nonsensical. She demonstrated simultanagnosia; e.g. when shown an advertisement in a

magazine she failed to grasp the meaning of the scene, but recognized the elements within the scene. Prosody was poor, and words were mispronounced in reading. She later confided that 'I lost my writing abilities in the operation. I used to be able to write without thinking about it; now I can't write easily any more'—this despite well-preserved orthography, as she was referring to the content of her writing, not the formation of the letters or words.

Neuropsychological testing was conducted 2 and 6 weeks post-surgery and provided further objective evidence for the cognitive impairments observed on bedside examination. At the first evaluation, she was notably impulsive, childlike and emotionally labile. IQ was markedly lower than the expectations based on educational history, with Verbal IQ falling in the borderline range and Performance IQ in the mentally deficient range. Cognitive impairments were global




Fig. 2 Distribution graphs of the Z-scores for patients (grouped according to disease type and location) showing their performance on neuropsychological tests. Diamonds represent bilateral PICA infarction; circles represent unilateral PICA infarction; squares represent SCA infarction; triangles represent cerebellitis and crosses represent cerebellar cortical atrophy. Abbreviations as in Table 3.

and diffuse at the first evaluation, and were evident in the areas of abstract reasoning and social judgment, remote memory, calculation skills, logical sequencing, visual-spatial organization, visual construction, confrontation naming and fluency. Foresight and planning were extremely poor, with performance on a maze task falling at an 8-year-old level. Visual memory was significantly impaired whereas ability to

remember verbal (story) information was normal. At the second evaluation, affective presentation remained abnormal, and the patient was observed to be passive, withdrawn and consistently flat. Sustained attention and concentration were also problematic, and she had a tendency to lose set in both verbal and non-verbal areas. Speech was fluent, but prosody compromised. Testing revealed improved functioning, mainly

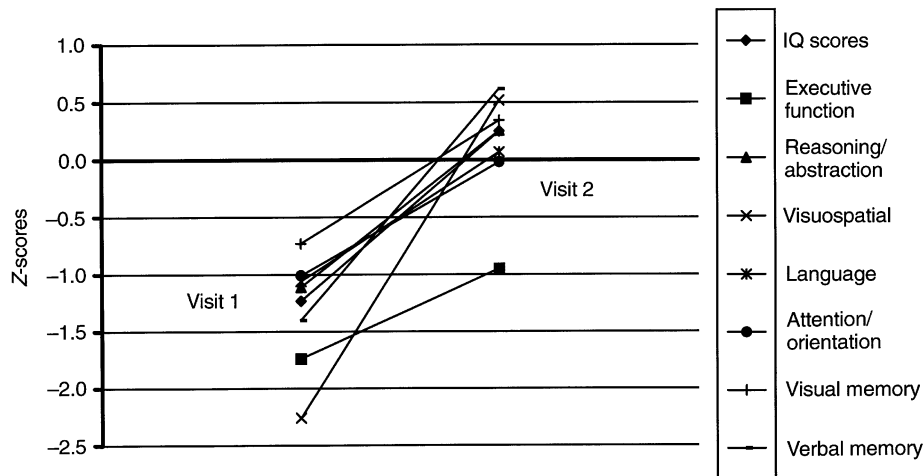


Fig. 3 Mean performances on neuropsychological tests in four patients (Cases 1, 3, 14, 15) tested within weeks of the acute insult (stroke or cerebellitis) are shown on the left, and the results of the same tests 1–9 months later are shown on the right.

in verbal reasoning and mental computation, verbal learning and recall and visual–spatial organization. Cognitive functions remained significantly compromised in several areas, including reasoning about social situations, visual memory, visuomotor integration, judgment of line orientation, pattern based reasoning, facial recognition, visuomotor tracking, executive functions and fine motor speed and dexterity.

There was some early improvement noticeable within a matter of 2–3 weeks, but the patient's mother was struck by her new inability to make even simple decisions, and her 'childish' behaviour. The various cognitive, personality and mood changes resolved slowly over a period of months, and she was able to return to a remedial course in a junior college programme 2 years following surgery.

Bilateral cerebellar infarction

Case 3. A 62-year-old right-handed attorney developed ataxia, nausea, vomiting, dysarthria and agitation. He was found to have a basilar artery thrombo-embolic infarction involving almost the entire right cerebellum (in the territory of the right PICA and the SCA) and the left cerebellar hemisphere (inferior and lateral, in the territory of the left-PICA). Patchy ischaemic changes were also seen in the medial aspect of both occipital lobes, but there were none seen in thalamus or elsewhere in the cerebral hemispheres by gadolinium enhanced and diffusion weighted MRI (Fig. 5).

There was no hydrocephalus. Two weeks after the stroke he was alert and co-operative. Nystagmus and saccadic pursuit were more marked on gaze to the right than to the left, and saccades were hypometric with catch-up saccades to both right and left. He had severe cerebellar dysarthria, mildly decreased tone in the extremities, and severe dysmetria with all tests of appendicular function, right more than left sides. He could sit unaided for only brief moments, and he needed two assistants to walk. Reflexes were normal, plantar

responses flexor, but he had strong bilateral palmar grasps and a snout reflex.

The patient's wife described a marked personality change since the stroke. On examination, he was alert and oriented. His affect alternated between either bland apathy or inappropriate familiarity. There were no paraphasic errors, and comprehension, repetition and reading were normal. He passed a formal test of attention ('letter A'), and a go–no-go task, although it was difficult to maintain his focus on the examiner and the tests being performed. He named 17 animals in 1 min, repeated six numbers forward and four in reverse sequence, these performances being borderline for his level of education. Verbal and visual learning and recall were intact. Praxis and calculation were intact. He failed to learn a delayed alternation test at the bedside despite repeated tries. He perseverated repeatedly in copying a two-loop diagram (Fig. 5). Visuospatial skill was impaired as he was unable to reproduce a simple arrangement of objects placed in front of him, even though the visual fields were full, visual acuity was normal, and he could see and describe the objects. Recovery of motor and cognitive findings was gradual and incomplete over the ensuing year. Speech took on the quality of a foreign accent, with unusual inflections. The patient remained disinhibited.

This patient received neuropsychological testing 2 weeks following his stroke, and 9 months later. At the initial evaluation, his presentation was notable for marked disinhibition, with frequent swearing, and attempts to kiss the examiner, as well as for a significant dysarthria and poor fine motor co-ordination. Test results provided evidence of significant impairments in the visual synthesis of information, logical sequencing of information, verbal short-term memory capacity, abstract reasoning and complex problem solving, and provided evidence of mildly impaired confrontation naming and verbal fluency. Performance was severely impaired on the Wisconsin Card Sorting Task, where he

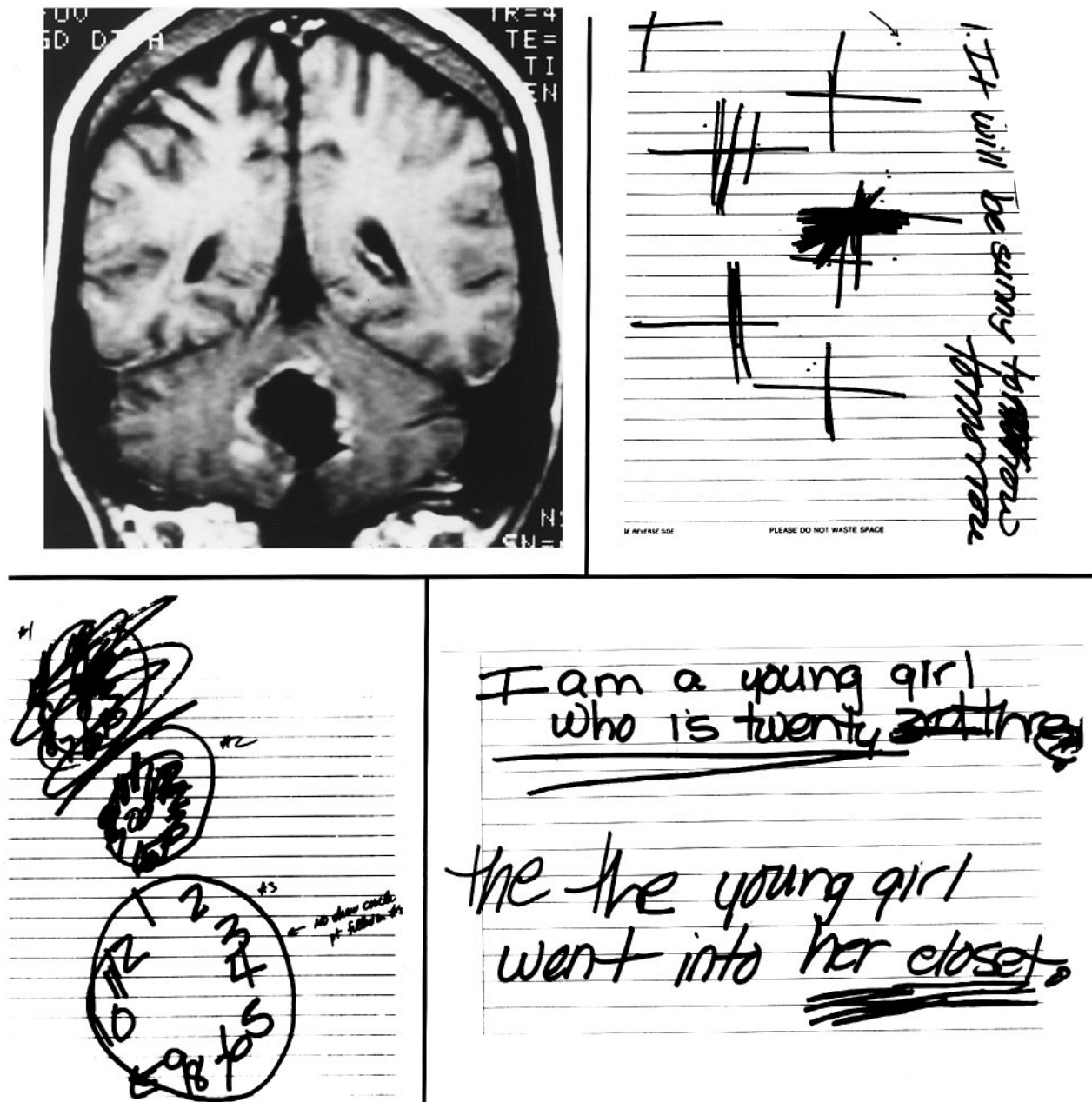


Fig. 4 T₁-weighted coronal MRI of the brain of Case 1 showing the site of excision of the ganglioglioma, and her responses when asked to bisect a line, draw a clock and write a sentence.

demonstrated a highly concrete approach, refusing to sort all but exact physical matches. At the second evaluation, marked improvements were evident in speech and fine motor functions, allowing for more complete assessment of cognitive functioning. Mild disinhibition was evident at this evaluation. Assessment of intellectual functioning revealed a high average Verbal IQ, and a significantly lower, but still average, Performance IQ. Improvements were evident in virtually all areas of cognitive functioning, although mild impairments remained in the areas of visuospatial organization, visual construction and visual memory.

Infarction in the territory of the right PICA

Case 4. A 34-year-old right-handed salesman with a 12th grade education developed vertebral artery dissection with infarction in the right posterior and inferior cerebellum in the territory of the right PICA. He presented with nausea, vomiting, vertigo and headache. When seen 2 days after the onset, he had rightward beating nystagmus on right lateral gaze, absent oculokinetic nystagmus to the right and hypermetric saccades to the right. Drowsiness and inattention with mild confusion heralded early hydrocephalus, and posterior fossa decompression was performed with excision

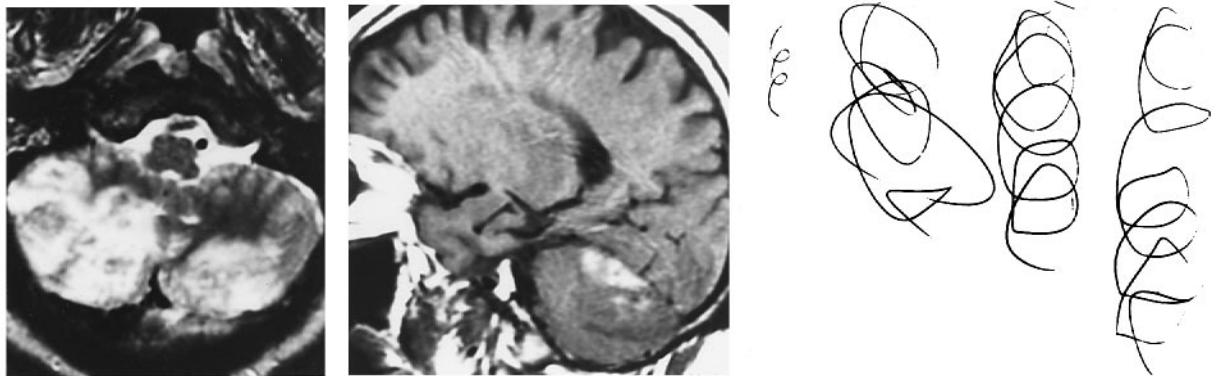


Fig. 5 T₂-weighted MRI images of the brain of Case 3 reveal infarction in the PICA territory bilaterally, in the axial section on the left, and in the territory of the right SCA, in the parasagittal image in the centre. Perseverative copying of a two-loop diagram is shown on the right.

of the infarcted right lateral cerebellar hemisphere and a portion of the right cerebellar tonsil. He was fully alert and oriented the day following surgery, with normal appearing cerebral ventricles on head CT scan. Two weeks after the stroke this patient's elementary examination showed only slightly hypermetric saccades to the right. His affect fluctuated between being markedly blunt and inappropriately jocular. He was concrete in his interpretation of proverbs, had difficulty performing the go-no-go task at the bedside, and had some perseveration with the Luria diagram. He asked the same questions repeatedly despite receiving full answers each time. His speech was telegraphic in content, dysprosodic, but not aphasic or dysarthric. Naming was poor, and his performance of the fist-palm-side test was impaired.

Neuropsychological evaluations were conducted 9 days and 3 months post-stroke. At the first evaluation, presentation was notable for a flat and unconcerned quality, and speech, while fluent was also notable for its flat tone. Overall level of intellectual functioning fell to within the low average range, with consistent performance in verbal and non-verbal domains. Lexical access was moderately impaired as was the ability to recall story information immediately. Delayed memory for verbal information fell outside normal limits, as did both immediate and delayed recall for visual information. Executive functions were severely impaired, as evidenced by very poor performance on the F-A-S (fluency) test, and on the Wisconsin Card Sorting Test. Ability to write a story was severely impaired, consisting of a non-integrated listing of observations. At the second evaluation, affect was more differentiated, although the patient appeared mildly euphoric. There was a marked improvement in cognitive abilities, with the level of intellectual functioning falling in the average to high average ranges. Significant gains were apparent in several areas including computation, verbal and visual memory, lexical access, visuospatial reasoning, visuomotor tracking, complex problem solving and narrative writing. Verbal reasoning, in contrast, remained relatively concrete, and attention to visual detail remained poor.

The SPECT scan 1 week after the stroke showed patchy hypoperfusion throughout both cerebral hemispheres (left

more than right), although visual cortices were well perfused. The basal ganglia were hypoperfused bilaterally, and perfusion was diminished bilaterally in thalamus but more so on the right. Six weeks after the stroke, the patient's family reported that he was moody, irritable, impulsive, unmotivated and inappropriate. At that time the elementary examination was normal, but he appeared quite flippant, and the SPECT scan showed essentially no change in the cerebral cortical hypoperfusion, although there was more robust perfusion of thalamus and basal ganglia bilaterally. According to the patient's family he did not return to his 'old self' until almost 6 months after the stroke.

Infarction in the territory of the AICA

Case 12. A 50-year-old right-handed woman suffered a stroke involving the right cerebellar hemisphere at the mid-to superior aspect, and the middle cerebellar peduncle, in the territory of the right AICA. She awoke with tinnitus, dysequilibrium and right sided inco-ordination, and mild dysarthria. She went to work that day, in her capacity as director of communications for a mutual fund company. She noted that her handwriting was almost illegible. In addition, she noted that her thought processes were slower, and she had to concentrate harder with more effortful thinking when looking at the quarterly reports. She had great difficulty in making financial decisions that are usually second nature to her. She would usually have 'multiple things going on at a time', but she found she was limited in the number of things she could think of at once. Instead, she 'had to let a bunch of things fall away'. These complaints related to the cognitive performance, associated with her difficulty writing and the need to concentrate carefully when talking, prompted her to seek medical attention later that day. Eight days after the stroke, she reported that she was still not thinking as quickly as normal, and she was less able to cope with more than one or two ideas or concepts at the same time. One of this patient's great pleasures was reading the classics (she holds a degree in English literature), a hobby she avidly pursued. However, since the stroke she stated that she was unable to

follow the stream of logic as swiftly as normal, and she had difficulty keeping track of the train of the thoughts in the narrative.

The elementary examination revealed only saccadic pursuit and overshoot/undershoot to the right, minimal dysmetria in the right arm and leg, a rare dysarthric word, and no agrammatism. She was fully oriented and conversant, learned and recalled four words at 5 min without difficulty, named alternating lists of fruits and vegetables, and named 17 animals in 45 s before giving up. She had difficulty with the fist–palm–side alternating sequences test. She made errors with both hands, and the hesitant and slow performance of the right hand was beyond that which would have been expected from the tests of coordination. She made an error in placing the hands on the clock, but drawings of objects and a floor plan of her house were otherwise reasonably preserved. This patient's report of slowed thought processing, more effortful thinking and concentration, and new difficulty with holding and manipulating simultaneous concepts in mind were her principal complaints. Neuropsychological testing was not performed.

Post-infectious cerebellitis

Case 15. A 20-year-old right-handed college student developed post-infectious cerebellitis following infectious mononucleosis (Epstein–Barr virus). The MRI and EEG were normal. She reported that one of her early symptoms was that when driving a car she found herself closer to other cars than she expected, and when walking she bumped into furniture because the items 'seemed to be much closer than (she) judged them to be'. Ten days into the course, there was a pancerebellar motor syndrome of moderate degree. Eye movements showed hypometric and hypermetric saccades, saccadic pursuit and failure to suppress the vestibulo-ocular-reflex. There was a mild dysarthria, mild appendicular (left more than right) and truncal ataxia, and a slow, wide-based ataxic gait. She interacted readily, but she had a flattened affect, and spontaneous conversation was limited. She learned four words on the first attempt, recalled three of these at 5 min, but could not remember the fourth despite being given a choice from a list. Verbal fluency was diminished. She generated the names of only 11 animals in 1 min, and only five cities (from anywhere in the world) in 1 min. She was unable to generate an alternating list of fruits and vegetables, in that she could not get beyond two pairs, and lost track of the task. There were multiple errors in the fist–palm–side test with either hand, and she could not sustain the alternating pattern. She corrected her errors in copying the Luria sequence. She made errors in copying a simple diagram, and was inaccurate in reproducing it from memory at 1 min; however, this visual recollection did not degrade when she drew it from memory again 5 min later. She demonstrated simultanagnosia in viewing a complex picture and the cookie jar scene, picking out elements of the diagram but not being able to grasp the essence of the scene. The

patient was treated with plasmapheresis twice weekly for 3 weeks, with both patient and family noting improvement in motor and cognitive symptoms during the day following each plasmapheresis. Her spirits became brighter, her speech was quicker and clearer, and her incoordination improved. After the final plasmapheresis session (3 weeks after first being examined), she was bright and interactive, was able to learn and recall four words without difficulty, recited the names of 22 animals in 1 min, and completed set shifting tasks well (fist–palm–side, and alternating lists without hesitation). Her visuospatial abilities also improved, as shown most clearly by the neuropsychological testing.

Neuropsychological evaluation was conducted 2 weeks, and again 2 months, after the onset of the cerebellitis. At the initial evaluation, testing revealed a significantly depressed overall level of functioning from estimated premorbid levels, with Full Scale IQ falling within the low average range, and a significant discrepancy observed between average range Verbal IQ and borderline range Performance IQ. Significant cognitive impairments were observed in the areas of visual spatial reasoning, visual construction, verbal fluency, planning and foresight, and verbal and visual attention. Behavioural presentation was notable both for a lack of insight into her difficulties and for a mild slurring of speech. Two months later, remarkable improvements in cognitive performance were observed. Full Scale IQ fell solidly within the average range, falling 21 points higher than at the initial evaluation. Verbal IQ fell within the high average range (a 15-point improvement) and Performance IQ in the average range (a 22-point improvement). Improvements were especially striking on a test of visual construction. At the initial evaluation, the copy of the Rey Complex Figure was highly fragmented, whereas at the second evaluation the copy of the Taylor figure was highly organized and accurate (Fig. 7). It is notable that the difficulties evident in her copy at the initial visit resulted from an inability to plan and appreciate the figure's organizing structure rather than from impairment of motor co-ordination.

Visual memory also significantly improved, as did visuomotor conceptual tracking and sequential reasoning. Verbal fluency improved mildly from the time of the first evaluation, but it remained impaired, as did performance on the California Verbal Learning Test, a relatively unstructured list learning and memory task.

Discussion

The clinical syndrome

The debate concerning the clinical relevance of the non-motor functions of the cerebellum has been hampered by the lack of data in patients showing a correlation between cerebellar damage and changes in behaviour. This paper describes clinically relevant behavioural manifestations in patients whose lesions are confined to the cerebellum. Our findings indicate that these behavioural changes can be

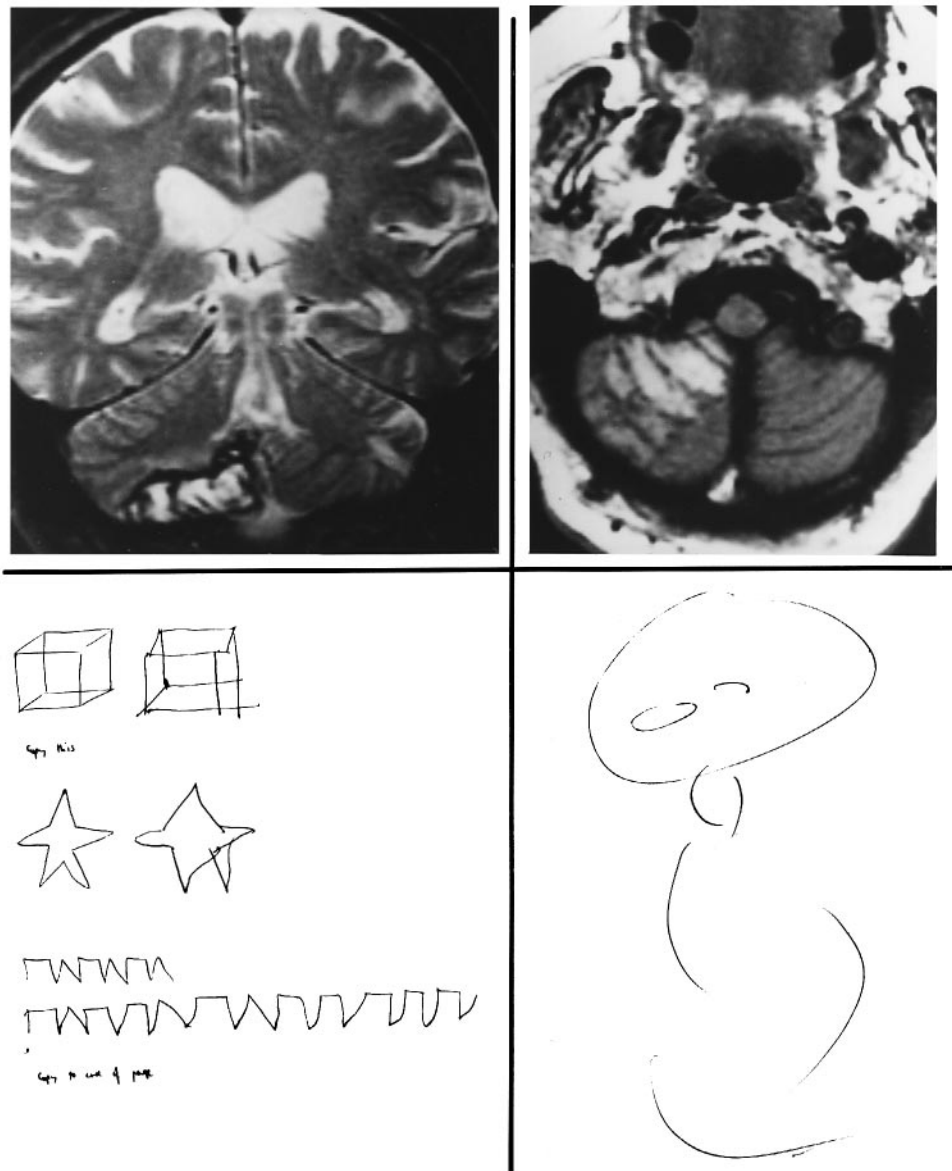


Fig. 6 Coronal (left) and axial (right) T₂-weighted MRI scans in Case 5, demonstrating haemorrhagic infarction in the territory of the right PICA. Also shown are this patient's copies of a cube, a five-pointed star and the Luria diagram, and his rendition of a person.

diagnosed at the bedside and quantified by neuropsychological tests, and they conform to an identifiable clinical syndrome that is consistent with predictions derived from anatomy, physiology and functional neuroimaging studies.

The cerebellar cognitive affective syndrome is characterized by the following. (i) Disturbances of executive function. This includes deficient planning, set-shifting, abstract reasoning, working memory, and decreased verbal fluency. (ii) Impaired spatial cognition, including visuospatial disorganization and impaired visuospatial memory. (iii) Personality change, characterized by flattening or blunting of affect, and disinhibited or inappropriate behaviour. (iv) Linguistic difficulties, including dysprosodia, agrammatism and mild anomia. The net effect of these disturbances

in cognitive functioning is a general lowering of overall intellectual function.

These core features of executive, spatial, linguistic and affective changes define the cerebellar cognitive affective syndrome and set it apart from non-specific confusional states or accepted notions of dementia. Arousal and alertness are not depressed. Remote episodic and semantic memory are preserved, and new learning is only mildly affected. Other 'cortical' phenomena are largely absent, such as aphasia, apraxia and agnosia. Furthermore, the cerebellar cognitive affective syndrome is distinguishable from other 'subcortical' syndromes by virtue of the symptom complex consisting of disturbances in executive, spatial, linguistic and affective functions.

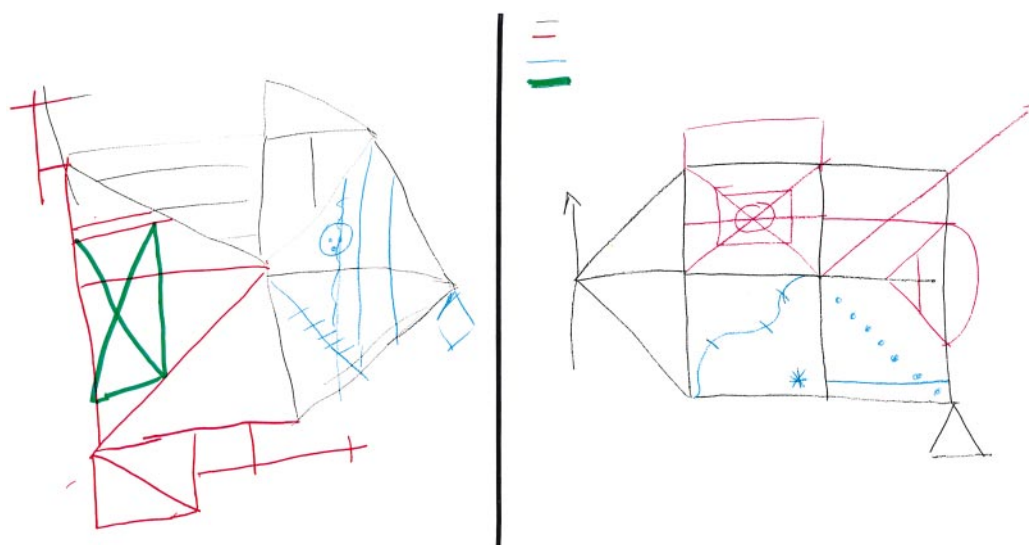


Fig. 7 Copies of the Rey complex figure, on the left, produced by Case 15 during the symptomatic phase of post-infectious cerebellitis; and of the Taylor figure of equivalent complexity, on the right, 3 months later when she had recovered.

It is important to note that these impairments were present on routine bedside mental state tests, and on standardized neuropsychological tests of cognitive function. A normal performance would have been anticipated had the patients not been cognitively impaired. In fact, the patients in this series had a relatively high educational background (mean = 13.9 years) and thus the premorbid performance would be expected to fall at or even above the normal mean. It is also important to note that the observed impairments cannot be explained by difficulties with motor control. In many cases motor incoordination was very mild as determined by clinical observation. Moreover, tests that were highly demanding of motor function were not administered to patients with moderate or severe dysmetria. Motor incapacity would not explain the abnormal Verbal IQ score (where responses are verbal and are untimed), the impairment of Picture Arrangement and Picture Completion (where the motor requirement is minimal) or the poor performance on the Boston Naming Test. On those neuropsychological tests in which there is a significant motor component, e.g. Rey Copy, Trail Making Tests and Porteus Mazes, it was apparent from our patients' performances that the locus of their difficulty was not the motor requirement of the task. For example, as shown in Fig. 7, the Rey copy for Patient 15 demonstrates that the difficulty resulted from an impaired ability to appreciate the organizing structure of the figure, and in planning the copy of the figure. The execution of the motor movements required to copy the design was, in contrast, quite unremarkable. Similarly, on the Porteus Mazes, patients did not have difficulty drawing the lines, but rather their errors resulted from poor planning, often going into blocked paths, and requiring several attempts to find the correct solution. These results suggest that these patients have difficulty with planning and integration of cognitive

responses. These deficits are not so subtle as to be detected only on high level cognitive tests. Rather, they were clinically relevant, noted by family members and nursing and medical staff, and were associated with detectable abnormalities in the bedside mental state examination.

The neurobehavioural presentation in our patients was more pronounced and generalized in patients with large, bilateral, or pancerebellar disorders, and particularly in those with acute onset cerebellar disease. It was less evident in patients with more insidious disease, in the recovery phase (3–4 months) after acute stroke, and in those with restricted cerebellar pathology. Lesions of the posterior lobe were particularly important in the generation of the disturbed cognitive behaviours, and the vermis was consistently involved in patients with pronounced affective presentations. The anterior lobe seemed to be less prominently involved in the generation of these cognitive and behavioural deficits. The one patient with an autonomic syndrome had a lesion involving the medial posterior lobe, including the fastigial nucleus. It is important to exercise caution in drawing conclusions regarding the details of the organization of these various functions within the cerebellum, however, because of the small sample size and the heterogeneity of the lesion type in this study. The correlation of each component of the cerebellar cognitive affective syndrome with the precise region of the cerebellum destroyed will depend on the analysis of a larger group of patients.

The responsible neural circuitry

The cognitive and affective abnormalities described in this report are those usually encountered in patients who have disorders of the cerebral hemispheres, and particularly, of the association areas and paralimbic regions, or disorders of

the subcortical areas with which they are interconnected. Thus, disturbances of executive function are usually encountered in patients with lesions of the prefrontal cortex; visuospatial deficits are seen following damage to the parietal lobe; decreased verbal fluency and linguistic processing difficulties are seen in the setting of either frontal or temporal lobe pathology; impaired visuospatial sequencing accompanies lesions of the right temporal lobe; and changes in affect and motivation commonly reflect disturbances in limbic related regions in the cingulate and parahippocampal gyri (see Critchley, 1953; Fuster, 1980; Mesulam, 1985). The presence of these cognitive deficits in patients with cerebellar lesions can be better understood when viewed in light of the anatomical connections linking the cerebral association areas and paralimbic regions with the cerebellum.

The cerebrocerebellar anatomical circuitry consists of a feedforward limb (the corticopontine and pontocerebellar pathways) and a feedback limb (the cerebellothalamic and thalamocortical systems). Anatomical investigations in the monkey have revealed pontine projections from sensorimotor cortices (Brodal, 1978; Glickstein *et al.*, 1985). More recently, strong and highly organized projections to the pons have been shown to arise from association areas in the dorsolateral and dorsomedial prefrontal cortex (Schmahmann and Pandya, 1995, 1997a), posterior parietal region (Brodal, 1978; Glickstein *et al.*, 1985; May and Andersen, 1986; Schmahmann and Pandya, 1989), superior temporal polymodal (Schmahmann and Pandya, 1991), posterior parahippocampal (Schmahmann and Pandya, 1993) and dorsal prestriate regions (Fries, 1990; Schmahmann and Pandya, 1993), as well as from the cingulate gyrus (Vilensky and van Hoesen, 1981). These anatomical studies are in agreement with earlier physiological observations, such as those of Allen and Tsukuhara (1974) and Sasaki *et al.* (1975), indicating the presence of parietal and prefrontal lobe connections with the cerebellar cortex. Furthermore, the medial mamillary bodies (implicated in memory) and deep layers of the superior colliculus (important for attention) have projections to the pons (Aas and Brodal, 1988) and reciprocal connections with the cerebellum (Haines and Dietrichs, 1984). Anatomical studies also reveal direct and reciprocal connections between the hypothalamus and cerebellum (Haines and Dietrichs, 1984), and early physiological studies concluded that the cerebellum contributes to the limbic circuitry including septal nuclei and hippocampus (Snider, 1950; Anand *et al.*, 1959; Harper and Heath, 1973; Snider and Maiti, 1976). The details of the pontocerebellar projections have yet to be elucidated, but the known anatomy of this system (Brodal, 1979) is in agreement with the conceptual notion that the associative cortices are linked with the more recently evolved lateral cerebellar hemispheres (Leiner *et al.*, 1986, 1993; Dow, 1988). The cerebellar feedback loop through thalamus to the cerebral cortex appears to be directed not only to sensorimotor cortices, but also to the same associative areas from which the feedforward limb originates (Schmahmann and Pandya, 1990; 1997b; Middleton and Strick, 1994, 1997). The demon-

stration of this associative cerebrocerebellar circuitry has led to the suggestion that the cerebellum is incorporated into the neural systems that subserve such higher order behaviour as working memory, executive function, visual spatial abilities, linguistic processing, memory, attention and emotional modulation (Schmahmann, 1991, 1996). The neuropsychological and affective disorders in patients with cerebellar lesions are likely to be a consequence of disruption of these anatomical connections.

Functional neuroimaging

The clinical observations in these patients are also compatible with the results of functional neuroimaging studies which address the question of cerebellar participation in cognitive tasks. Cerebellar activation has been observed during tests of language function including verb for noun substitution (Petersen *et al.*, 1989) and synonym generation (Klein *et al.*, 1995). Other cognitive tasks that have been studied specifically for the degree to which they produce cerebellar activation include working memory (Klingberg *et al.*, 1995; Desmond *et al.*, 1997), verbal memory (Grasby *et al.*, 1993; Andreasen *et al.*, 1996), classical conditioning (Logan and Grafton, 1995), mental imagery (Ryding *et al.*, 1993; Mellet *et al.*, 1995; Parsons *et al.*, 1995), shifting attention (Allen *et al.*, 1997), cognitive planning (Kim *et al.*, 1994), sensory discrimination (Gao *et al.*, 1996) and emotional modulation (Reiman *et al.*, 1989; Bench *et al.*, 1992; Dolan *et al.*, 1992; George *et al.*, 1995; Mayberg *et al.*, 1995). The cerebellum is also activated during the early phases of acquisition of a motor skill (Seitz and Roland, 1992; Jenkins *et al.*, 1994; Doyon *et al.*, 1997), a finding supported by the recent demonstration that procedural learning is impaired in patients with focal cerebellar lesions (Molinari *et al.*, 1997). Some generalizations concerning the anatomical distribution within the cerebellum of these different functions can be derived such that crus I anterior and posterior (of the ansiform lobule) on the right and vermal lobule VIIA-f (the folium) are activated during linguistic tasks, and shifting attention seems to activate crus I anterior on the left (according to the atlas of Schmahmann *et al.*, 1996). This notwithstanding, the precise organization of these cognitive and affective functions remains to be elucidated.

Diaschisis and the functional role of the cerebellum

Reversed cerebellar diaschisis documented by areas of hypoperfusion in cerebral association areas was seen on PET/SPECT in each of the three patients in whom this was assessed. Hypoperfused regions were noted in the parietal, temporal and prefrontal cortices, and alterations in perfusion were also noted in thalamus and basal ganglia. Cerebral hypoperfusion on PET/SPECT has also been observed in other studies of cerebellar patients (Botez *et al.*, 1991). These

observations are important because it is impossible on the basis of these cases to distinguish the contribution of the lesioned cerebellum to these abnormal behaviours from that of the cerebral regions newly deprived of their connections with the cerebellum. Furthermore, the recovery of function documented by neuropsychological tests in four patients with acute lesions in this series, and observed clinically in others, indicates that the disruption of behaviour by cerebellar lesions is, to some extent, transient. The natural history of the cognitive and affective deficits following acute cerebellar lesions will need to be established by a larger, prospective, longitudinal study.

Diaschisis and functional recovery notwithstanding, the existence of a definable cerebellar cognitive affective syndrome following acute lesions confined to the cerebellum implies that these lesions are causally related to the generation of clinically abnormal behaviour. In addition, the functional imaging, physiological and neuroanatomical studies cited above suggest that there is a role for the cerebellum in the organization of normal behaviours. Precisely what that cerebellar role is, and how the cerebellum accomplishes it, is yet to be established, and the clinical syndrome described here does not settle this issue. We have hypothesized (Schmahmann and Pandya, 1989; Schmahmann, 1991, 1996) that the multiple highly organized anatomical subsystems that constitute the cerebrotocerebellar circuit represent functional subsystems that facilitate cerebellar processing in many different functional domains, be they motor, sensory, cognitive, affective or autonomic. The proposed net effect of these multiple streams of diverse information reaching into, and being sent back from, the cerebellum is that the cerebellum is able to integrate multiple internal representations with external stimuli and self-generated responses. The cerebellar modulation of these different subsystems permits the ultimate production of harmonious motor, cognitive, and affective/autonomic behaviours. The findings of the present study suggest that the loss of the cerebellar component of these neural circuits produces a dysmetria of thought (Schmahmann, 1991, 1996) that results in the cerebellar cognitive affective syndrome.

Acknowledgements

The authors are grateful to Ms Amy Hurwitz for her assistance with the technical and statistical aspects of this paper. Cheri Geckler, PhD performed the neuropsychological studies on some of the early cases in this series. The valuable critiques of this work by Dr David Caplan are greatly appreciated. This work was presented in part at the Human Brain Mapping Meeting, Paris, France, July 1995; and at the Society for Neuroscience, New Orleans, Louisiana, October 1997.

References

Aas J-E, Brodal P. Demonstration of topographically organized projections from the hypothalamus to the pontine nuclei: an

experimental anatomical study in the cat. *J Comp Neurol* 1988; 268: 313–28.

Alekoubides A, Charter RA, Adkins TG, Seacat GF. The diagnosis of brain damage by the WAIS, WMS, and Reitan Battery utilizing standardized scores corrected for age and education. *Int J Clin Neuropsychol* 1987; 9: 11–28.

Allen GI, Tsukahara N. Cerebrotocerebellar communication systems. [Review]. *Physiol Rev* 1974; 54: 957–1006.

Allen G, Buxton RB, Wong EC, Courchesne E. Attentional activation of the cerebellum independent of motor involvement. *Science* 1997; 275: 1940–3.

Amarenco P. The spectrum of cerebellar infarctions. *Neurology* 1991; 41: 973–9.

Anand BK, Malhotra CL, Singh B, Dua S. Cerebellar projections to limbic system. *J Neurophysiol* 1959; 22: 451–57.

Andral G. *Clinique médicale*, Vol. 5. 4th ed. Paris: Fortin, Masson et Cie; 1848.

Andreasen NC, O'Leary DS, Cizadlo T, Arndt S, Rezai K, Ponto LL, et al. Schizophrenia and cognitive dysmetria: a positron-emission tomography study of dysfunctional prefrontal-thalamic-cerebellar circuitry. *Proc Natl Acad Sci USA* 1996; 93: 9985–90.

Army Individual Test Battery. *Manual of Directions and Scoring*. Washington (DC): War Department, Adjutant General; 1944.

Appollonio IM, Grafman J, Schwartz V, Massaquoi S, Hallett M. Memory in patients with cerebellar degeneration. *Neurology* 1993; 43: 1536–44.

Bauman M, Kemper TL. Histoanatomic observations of the brain in early infantile autism. *Neurology* 1985; 35: 866–74.

Bench CJ, Friston KJ, Brown RG, Scott LC, Frackowiak RS, Dolan RJ. The anatomy of melancholia. Focal abnormalities of cerebral blood flow in major depression. *Psychol Med* 1992; 22: 607–15.

Benton AL, Hamsher K de S, Varney NR, Spreen, O. *Contributions to neuropsychological assessment: a clinical manual*. New York: Oxford University Press; 1983.

Botez MI, Gravel J, Attig E, Vezina J-L. Reversible chronic cerebellar ataxia after phenytoin intoxication: Possible role of cerebellum in cognitive thought. *Neurology* 1985; 35: 1152–7.

Botez MI, Léveillé J, Lambert R, Botez T. Single photon emission computed tomography (SPECT) in cerebellar disease: cerebello-cerebral diaschisis. *Eur Neurol* 1991; 31: 405–21.

Botez-Marquard T, Léveillé J, Botez MI. Neuropsychological functioning in unilateral cerebellar damage. *Can J Neurol Sci* 1994; 21: 353–7.

Bracke-Tolkmitt R, Linden A, Canavan AG, Rockstroh B, Scholz E, Wessel K, et al. The cerebellum contributes to mental skills. *Behav Neurosci* 1989; 103: 442–6.

Brodal P. The corticopontine projection in the rhesus monkey. Origin and principles of organization. *Brain* 1978; 101: 251–83.

Brodal P. The pontocerebellar projection in the rhesus monkey: an experimental study with retrograde axonal transport of horseradish peroxidase. *Neuroscience* 1979; 4: 193–208.

- Combettes. Absence complète du cervelet, des pédoncules postérieurs et de la protubérance cérébrale chez une jeune fille morte dans sa onzième année. *Bull Soc Anat Paris* 1831; 5: 148–57.
- Courchesne E, Yeung-Courchesne R, Press GA, Hesselink JR, Jernigan TL. Hypoplasia of cerebellar vermal lobules VI and VII in autism. *N Engl J Med* 1988; 318: 1349–54.
- Critchley M. The parietal lobes. New York: Hafner Press; 1953.
- Delis DC, Kramer JH, Kaplan E, Ober BA. California Verbal Learning Test, Form 11 (Research Edition). San Antonio (TX): Psychological Corporation; 1987.
- Desmond JE, Gabrieli JD, Wagner AD, Ginier BL, Glover GH. Lobular patterns of cerebellar activation in verbal working-memory and finger-tapping tasks as revealed by functional MRI. *J Neurosci* 1997; 17: 9675–85.
- Dolan RJ, Bench CJ, Brown RG, Scott LC, Friston KJ, Frackowiak RS. Regional cerebral blood flow abnormalities in depressed patients with cognitive impairment. *J Neurol Neurosurg Psychiatry* 1992; 55: 768–73.
- Dow RS. Contribution of electrophysiological studies to cerebellar physiology. [Review]. *J Clin Neurophysiol* 1988; 5: 307–23.
- Dow RS, Moruzzi G. The physiology and pathology of the cerebellum. Minneapolis: University of Minnesota Press; 1958.
- Doyon J, Gaudreau D, Laforce R Jr, Castonguay M, Bedard PJ, Bedard F, Bouchard J-P. Role of the striatum, cerebellum and frontal lobes in the learning of a visuomotor sequence. *Brain Cogn* 1997; 34: 218–45.
- Dunn LM, Dunn LM. Peabody Picture Vocabulary Test-Revised Manual. Circle Pines (MN): American Guidance Service; 1981.
- Fiez JA, Petersen SE, Cheney MK, Raichle ME. Impaired non-motor learning and error detection associated with cerebellar damage. *Brain* 1992; 115: 155–78.
- Fiez JA, Raichle ME. Linguistic processing. In: Schmahmann JD, editor. *The cerebellum and cognition. International Review of Neurobiology*, Vol. 41. San Diego: Academic Press; 1997. p. 233–54.
- Flourens MJP. Recherches expérimentales sur les propriétés et les fonctions du système nerveux dans les animaux vertébrés. Paris: Crevot; 1824.
- Fries W. Pontine projection from striate and prestriate visual cortex in the macaque monkey: an anterograde study. *Vis Neurosci* 1990; 4: 205–16.
- Fuster JM. The prefrontal cortex: anatomy, physiology and neuropsychology of the frontal lobe. New York: Raven Press; 1980.
- Gao J-H, Parsons LM, Bower JM, Xiong J, Li J, Fox PT. Cerebellum implicated in sensory acquisition and discrimination rather than motor control [see comments]. *Science* 1996; 272: 545–7. Comment in: *Science* 1996; 272: 482–3.
- George MS, Ketter TA, Parekh PI, Horwitz B, Herscovitch P, Post RM. Brain activity during transient sadness and happiness in healthy women. *Am J Psychiatry* 1995; 152: 341–51.
- Glickstein M, May JG 3d, Mercier BE. Corticopontine projection in the macaque: the distribution of labelled cortical cells after large injections of horseradish peroxidase in the pontine nuclei. *J Comp Neurol* 1985; 235: 343–59.
- Golden CJ. Stroop Color and Word Test: a manual for clinical and experimental uses. Chicago (IL): Stoelting; 1978.
- Grafman J, Litvan I, Massaquoi S, Stewart M, Sirigu A, Hallett M. Cognitive planning deficit in patients with cerebellar atrophy [see comments]. *Neurology* 1992; 42: 1493–6. Comment in: *Neurology* 1993; 43: 2153–4.
- Grasby PM, Frith CD, Friston KJ, Bench C, Frackowiak RS, Dolan RJ. Functional mapping of brain areas implicated in auditory-verbal memory function. *Brain* 1993; 116: 1–20.
- Haines DE, Dietrichs E. An HRP study of hypothalamo-cerebellar and cerebello-hypothalamic connections in squirrel monkey (*Saimiri sciureus*). *J Comp Neurol* 1984; 229: 559–75.
- Harper JW, Heath RG. Anatomic connections of the fastigial nucleus to the rostral forebrain in the cat. *Exp Neurol* 1973; 39: 285–92.
- Heath RG, Franklin DE, Shraberg D. Gross pathology of the cerebellum in patients diagnosed and treated as functional psychiatric disorders. *J Nerv Ment Dis* 1979; 167: 585–92.
- Heaton RK, Chelune GJ, Talley JL, Kay GG, Curtiss G. Wisconsin Card Sorting Test Manual. Odessa (FL): Psychological Assessment Resources; 1993.
- Hodges JR. Cognitive assessment for clinicians. Oxford: Oxford University Press; 1994.
- Holmes G. A form of familial degeneration of the cerebellum. *Brain* 1907; 30: 466–88.
- Hooper HE. Hooper Visual Organization Test (VOT) Manual. Los Angeles: Western Psychological Services; 1983.
- Jenkins IH, Brooks DJ, Nixon PD, Frackowiak RS, Passingham RE. Motor sequence learning: a study with positron emission tomography. *J Neurosci* 1994; 14: 3775–90.
- Kaplan EF, Goodglass H, Weintraub S. The Boston Naming Test. 2nd ed. Philadelphia: Lea & Febiger; 1983.
- Kim SG, Ugurbil K, Strick PL. Activation of a cerebellar output nucleus during cognitive processing. *Science* 1994; 265: 949–51.
- Kingma A, Mooij JJ, Metzemaekers JD, Leeuw JA. Transient mutism and speech disorders after posterior fossa surgery in children with brain tumors. *Acta Neurochir (Wien)* 1994; 131: 74–9.
- Kish SJ, el-Awar M, Schut L, Leach L, Oscar-Berman M, Freedman M. Cognitive deficits in olivopontocerebellar atrophy: implications for the cholinergic hypothesis of Alzheimer's dementia. *Ann Neurol* 1988; 24: 200–6.
- Klein D, Milner B, Zatorre RJ, Meyer E, Evans AC. The neural substrates underlying word generation: a bilingual functional-imaging study. *Proc Natl Acad Sci USA* 1995; 92: 2899–903.
- Klingberg T, Roland PE, Kawashima R. The neural correlates of the central executive function during working memory—a PET study. *Hum Brain Mapp* 1995; Suppl 1: 414.
- Knoepfel HK, Macken J. Le syndrome psycho-organique dans les hérédo-ataxies. *J Belge Neurol Psychiat* 1947; 47: 314–23.

- Kolb B, Whishaw IQ. *Fundamentals of human neuropsychology*. 2nd ed. New York: W.H. Freeman; 1985.
- Leiner HC, Leiner AL, Dow RS. Does the cerebellum contribute to mental skills? *Behav Neurosci* 1986; 100: 443–54.
- Leiner HC, Leiner AL, Dow RS. Cognitive and language functions of the human cerebellum [see comments]. [Review]. *Trends Neurosci* 1993; 16: 444–7. Comment in: *Trends Neurosci* 1993; 16: 448–54.
- Levisohn L, Cronin-Golomb A, Schmahmann JD. Neuropsychological sequelae of cerebellar tumors in children [abstract]. *Soc Neurosci Abstr* 1997; 23: 496.
- Logan CG, Grafton ST. Functional anatomy of human eyeblink conditioning determined with regional cerebral glucose metabolism and positron-emission tomography. *Proc Natl Acad Sci USA* 1995; 92: 7500–4.
- Luciani L. *Il cervelletto. Nuovi studi di fisiologia normale e patologica*. Firenze: Le Monnier; 1891.
- May JG, Andersen RA. Different patterns of corticopontine projections from separate cortical fields within the inferior parietal lobule and dorsal prelunate gyrus of the macaque. *Exp Brain Res* 1986; 63: 265–78.
- Mayberg HS, Liotti M, Jerabek PA, Martin CC, Fox PT. Induced sadness: a PET model of depression [abstract]. *Hum Brain Mapp* 1995; Suppl 1: 396.
- Mellet E, Crivello F, Tzourio N, Joliot M, Petit L, Laurier L, et al. Construction of mental images based on verbal description: functional neuroanatomy with PET [abstract]. *Hum Brain Mapp* 1995; Suppl 1: 273.
- Mesulam M-M. *Principles of behavioral neurology*. Philadelphia: F.A. Davis; 1985.
- Middleton FA, Strick PL. Anatomical evidence for cerebellar and basal ganglia involvement in higher cognitive function. *Science* 1994; 266: 458–61.
- Middleton FA, Strick PL. Cerebellar output channels. In: Schmahmann JD, editor. *The cerebellum and cognition*. International Review of Neurobiology, Vol. 41. San Diego: Academic Press; 1997. p. 61–82.
- Molinari M, Leggio MG, Solida A, Ciorra R, Misciagna S, Silveri MC, et al. Cerebellum and procedural learning: evidence from focal cerebellar lesions. *Brain* 1997; 120: 1753–62.
- Parsons LM, Fox PT. Sensory and cognitive functions. In: Schmahmann JD, editor. *The cerebellum and cognition*. International Review of Neurobiology, Vol. 41. San Diego: Academic Press; 1997. p. 255–71.
- Parsons LM, Fox PT, Downs JH, Glass T, Hirsch TB, Martin CC, et al. Use of implicit motor imagery for visual shape discrimination as revealed by PET. *Nature* 1995; 375: 54–8.
- Petersen SE, Fox PT, Posner MI, Mintum MA, Raichle ME. Positron emission tomographic studies of the processing of single words. *J Cogn Neurosci* 1989; 1: 153–70.
- Pollack IF, Polinko P, Albright AL, Towbin R, Fitz C. Mutism and pseudobulbar symptoms after resection of posterior fossa tumors in children: incidence and pathophysiology [see comments]. *Neurosurgery* 1995; 37: 885–93. Comment in: *Neurosurgery* 1996; 38: 1066.
- Porteus SD. *Porteus Maze Test. Fifty years' application*. New York: Psychological Corporation; 1965.
- Raven JC, Court JH, Raven J. *Manual for Raven's Progressive Matrices and Vocabulary Scales*. London: HK Lewis and Co, 1977.
- Reiman EM, Raichle ME, Robins E, Mintun MA, Fusselman MJ, Fox PT, et al. Neuroanatomical correlates of a lactate-induced anxiety attack. *Arch Gen Psychiatry* 1989; 46: 493–500.
- Reitan RM. *Manual for administration of neuropsychological test batteries for adults and children*. Tucson (AZ): Reitan Neuropsychological Laboratory; 1979.
- Rey A. Psychological examination of traumatic encephalopathy. *Arch Psychol Genève* 1941; 28: 286–340.
- Ryding E, Decety J, Sjöholm H, Sternberg G, Ingvar DH. Motor imagery activates the cerebellum regionally. *Brain Res Cogn Brain Res* 1993; 1: 94–9.
- Sasaki K, Oka H, Matsuda Y, Shimono T, Mizuno N. Electrophysiological studies of the projections from the parietal association area to the cerebellar cortex. *Exp Brain Res* 1975; 23: 91–102.
- Schmahmann JD. An emerging concept: the cerebellar contribution to higher function [see comments]. [Review]. *Arch Neurol* 1991; 48: 1178–87. Comment in: *Arch Neurol* 1992; 49: 1229–30.
- Schmahmann JD. From movement to thought: anatomic substrates of the cerebellar contribution to cognitive processing. *Hum Brain Mapp* 1996; 4: 174–98.
- Schmahmann JD. Rediscovery of an early concept. In: Schmahmann JD, editor. *The cerebellum and cognition*. International Review of Neurobiology, Vol. 41. San Diego: Academic Press; 1997a. p. 3–27.
- Schmahmann JD (editor). *The cerebellum and cognition*. International Review of Neurobiology, Vol. 41. San Diego: Academic Press; 1997b.
- Schmahmann JD, Pandya DN. Anatomical investigation of projections to the basis pontis from posterior parietal association cortices in rhesus monkey. *J Comp Neurol* 1989; 289: 53–73.
- Schmahmann JD, Pandya DN. Anatomical investigation of projections from the thalamus to the posterior parietal cortices in the rhesus monkey. *J Comp Neurol* 1990; 295: 299–326.
- Schmahmann JD, Pandya DN. Projections to the basis pontis from the superior temporal sulcus and superior temporal region in the rhesus monkey. *J Comp Neurol* 1991; 308: 224–48.
- Schmahmann JD, Pandya DN. Prelunate, occipitotemporal, and parahippocampal projections to the basis pontis in rhesus monkey. *J Comp Neurol* 1993; 337: 94–112.
- Schmahmann JD, Pandya DN. Prefrontal cortex projections to the basilar pons in rhesus monkey: implications for the cerebellar contribution to higher function. *Neurosci Lett* 1995; 199: 175–8.
- Schmahmann JD, Pandya DN. Anatomic organization of the basilar pontine projections from prefrontal cortices in rhesus monkey. *J Neurosci* 1997a; 17: 438–58.
- Schmahmann JD, Pandya DN. The cerebrocerebellar system. In:

- Schmahmann JD, editor. *The cerebellum and cognition*. International Review of Neurobiology, Vol. 41. San Diego: Academic Press; 1997b. p. 31–60.
- Schmahmann JD, Doyon J, Holmes C, Makris N, Petrides M, Kennedy DN, Evans AC. An MRI atlas of the human cerebellum in Talairach space. *NeuroImage* 1996; 3(2): 122.
- Seitz RJ, Roland PE. Learning of sequential finger movements in man: a combined kinematic and positron emission tomography (PET) study. *Eur J Neurosci* 1992; 4: 154–65.
- Shallice T. Specific impairments of planning. *Philos Trans R Soc Lond B Biol Sci* 1982; 298: 199–209.
- Shallice T, Burgess P. Higher-order cognitive impairments and frontal lobe lesions in man. In: Levin HS, Eisenberg HM, Benton AL, editors. *Frontal lobe function and dysfunction*. New York: Oxford University Press; 1991. p. 125–38.
- Silveri MC, Leggio MG, Molinari M. The cerebellum contributes to linguistic production: a case of agrammatic speech following a right cerebellar lesion [see comments]. *Neurology* 1994; 44: 2047–50. Comment in: *Neurology* 1994; 44: 2001–5.
- Snider RS. Recent contributions to the anatomy and physiology of the cerebellum. *Arch Neurol Psychiatry* 1950; 64: 196–219.
- Snider RS, Maiti A. Cerebellar contribution to the Papez circuit. *J Neurosci Res* 1976; 2: 133–46.
- Spreen O, Strauss E. *A compendium of neuropsychological tests*. New York: Oxford University Press; 1991.
- van Dongen HR, Catsman-Berrevoets CE, van Mourik M. The syndrome of ‘cerebellar’ mutism and subsequent dysarthria [see comments]. *Neurology* 1994; 44: 2040–6. Comment in: *Neurology* 1994; 44: 2001–5.
- Vilensky JA, van Hoesen GW. Corticopontine projections from the cingulate cortex in the rhesus monkey. *Brain Res* 1981; 205: 391–5.
- Wallesch C-W, Horn A. Long-term effects of cerebellar pathology on cognitive functions. *Brain Cogn* 1990; 14: 19–25.
- Watson PJ. Nonmotor functions of the cerebellum. *Psych Bull* 1978; 85: 944–67.
- Wechsler D. *WAIS-R Manual*. New York: Psychological Corporation; 1981.
- Wechsler D. *Wechsler Memory Scale-Revised manual*. San Antonio (TX): Psychological Corporation; 1987.
- Wechsler D. *Wechsler Intelligence Scale for Children*. 3rd ed. San Antonio (TX): Psychological Corporation; 1991.
- Weintraub S, Mesulam M-M. Mental state assessment of young and elderly adults in behavioral neurology. In: *Principles of behavioral neurology*. Mesulam M-M, editor. Philadelphia: F.A. Davis; 1985. p. 71–123.
- Wilkinson GS. *WRAT3 Administration Manual*. Wilmington (DE): Wide Range; 1993.
- Yeudall LT, Fromm D, Reddon JR, Stefanyk WO. Normative data stratified by age and sex for 12 neuropsychological tests. *J Clin Psychol* 1986; 42: 918–46.

*Received August 11, 1997, Revised November 14, 1997.
Accepted January 2, 1998*